

Jigsaw Cambridgeshire Best Practice Users' Guide

Identifying Common Animal Bones from Archaeological Sites: A Brief Introduction

Chris Faine



April 2013

Animal bone is one of, if not the most, commonly recovered finds material from archaeological sites. Identifying the full range of species that you could potentially find on an archaeological site requires access to a comparative collection and hours of study gaining experience with archaeological material. Whilst this is beyond the scope of a short introduction, having the knowledge to identify the most commonly found species can be of great help on site. This guide will hopefully enable you to distinguish between human and animal bones and broadly distinguish between cattle, horse, sheep, pig and dog remains.

1 HUMAN VERSUS ANIMAL REMAINS

Distinguishing between human and animal bones whilst still on site is important for many reasons, not least of them legal (burial licences etc.). Whilst identifying complete bones seems relatively simple, fragmentary remains can be surprisingly difficult. The following differences can help you make the correct identification:

Cranium

| Human | Animal |
|---|---|
| Large bulbous vault, small face | Small vault, large face |
| Vault relatively smooth | Pronounced muscle markings, sagittal crest inferior |
| Inferior Foramen Magnum | Posterior Foramen Magnum |
| Chin present | Chin absent |
| Orbits at front, above nasal aperture | Orbits at sides, posterior to nasal aperture |
| Minimal nasal and midface projection | Significant nasal and midface projection |
| “U”-shaped mandible (no midline separation) | “V”-shaped mandible (separates at midline) |

Teeth

| Human | Animal |
|--|---|
| Omnivorous | Carnivorous, Herbivorous, Omnivorous |
| Dental formula 2:1:2:3 | Basic dental formula 3:1:4:3 |
| Incisors (maxillary) are larger than other mammals | Horse maxillary incisors are larger than human incisors |
| Canines small | Carnivores have large conical canines Herbivores have small or missing canines |
| Premolars and molars have low, rounded cusps divided by distinct grooves | Carnivores have sharp, pointed cheek teeth; Herbivores have broad, flat cheek teeth with parallel furrows and ridges |

Post Cranial

| Human | Animal |
|---|--|
| Upper limbs less robust | Robust upper limbs |
| Radius and ulna are separate bones | Radius and ulna often fused |
| Large, flat and broad vertebral bodies with short spinous processes | Small vertebral bodies with convex/concave surfaces and long spinous processes |
| Sacrum with 5 fused vertebrae, short and broad | Sacrum with 3 or 4 fused vertebrae, long and narrow |
| Pelvis is broad and short, bowl-shaped | Pelvis is long and narrow, blade-shaped |
| Femur is longest bone in body, linea aspera is singular feature | Femur is similar length to other limb bones, linea aspera double or plateau |
| Separate tibia and fibula | Tibia and fibula are often fused |
| Foot is long and narrow, weight borne on heel and toes | Foot is broad, weight borne mainly on toes |

2 IDENTIFYING THE MAIN DOMESTIC MAMMALS

Whilst size can be a useful guide initially don't rely on it completely. Shapes and sizes of most domestic breeds have changed considerably over time with the differences between modern and older breeds being often quite pronounced. For example the difference in average height at the shoulder between Iron Age and Modern cattle can be as much as 40cm!

Cattle versus Horse

Fragmentary cattle and horse remains are often confused given their similarity in size but there are several elements that demonstrate significant differences (aside from the horns!). **Figure 1** shows the skulls of the two species. The most important differences to note are the much smaller skull vault in horses compared to cattle and the difference jaw shape. The front of the skull will be much flatter and broader in cattle as well. If teeth are available then identification is much easier, with teeth of the two species (particularly molars) being very different. These can be seen in **Figure 2**. As one can see horse teeth are much squarer in profile and plan compared to cattle teeth with a radically different enamel fold pattern.

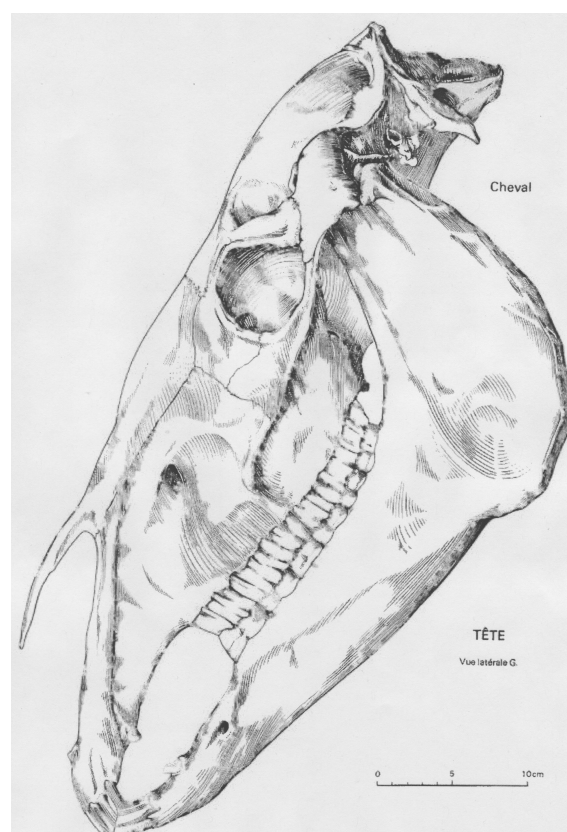
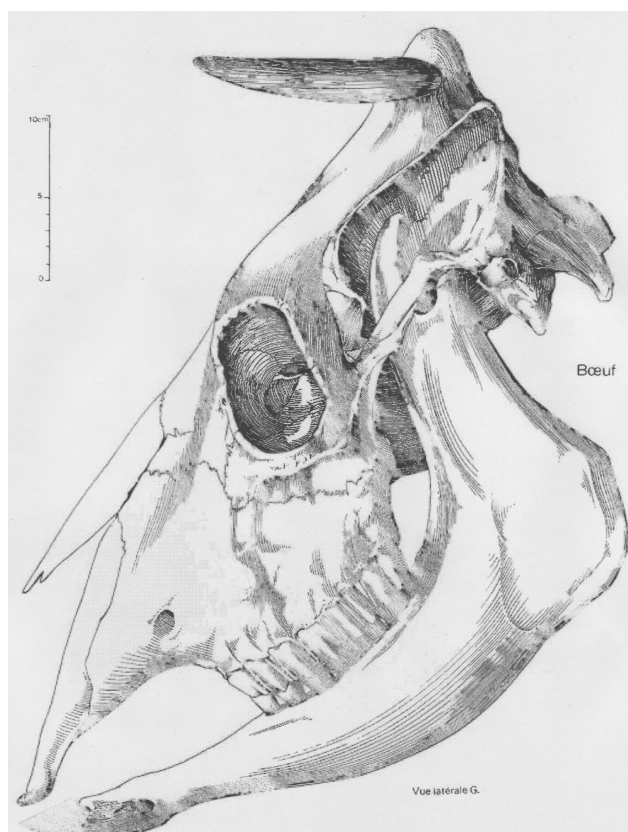

Figure 1: Cattle (L) and horse (R) skulls

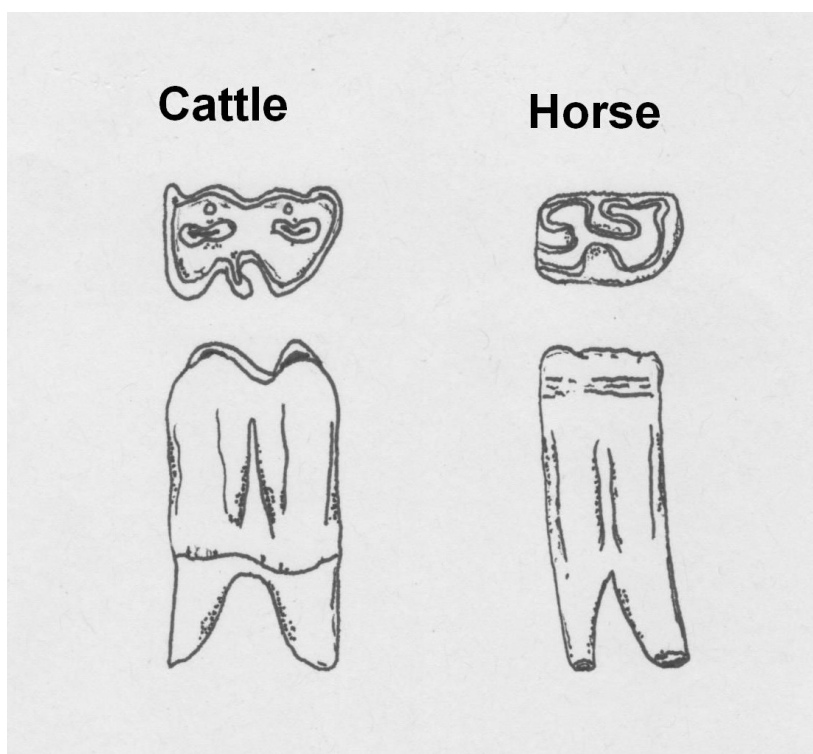


Figure 2: Cattle and horse 1st molars (lower)

Cattle and horse long bones also show very distinct differences especially (but not exclusively) femora and metapodials. **Figure 3** shows cattle and horse femora. The most apparent difference in these bones is the much larger muscle attachments at the proximal end of the horse femur compared to cattle (horses run faster than cattle!). Differences in metapodia are also a result of physiology (see **Figure 4**). Cattle belong to the group of mammals known as *artiodactyla*, (even toed hoofed mammals), whereas horses belong to the group *Perissodactyla* (odd toed hoofed mammals). As one can see in **Figure 4**, cattle metacarpals are formed of two fused bones leaving a groove between the two. Horse 1st metacarpals consist of a single bone. Cattle have two hooves leading to the distinctive double “cotton reel” at the distal end whilst the horses only display a single “cotton reel” because of the single hoof. Cattle and horse astralagi are also distinctive (see **Figure 5**).

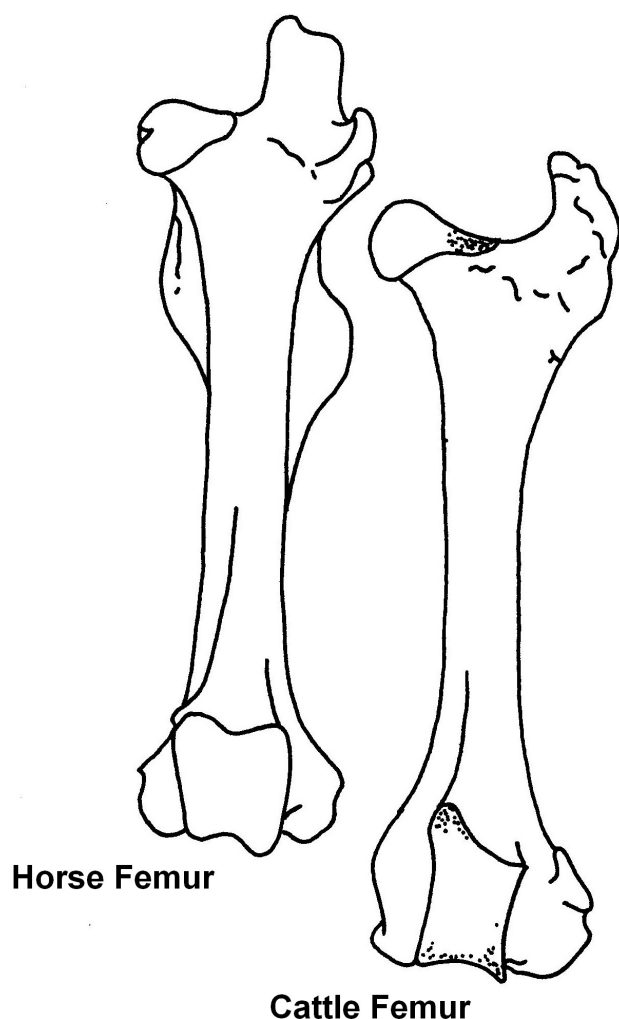


Figure 3: Horse and cattle femurs

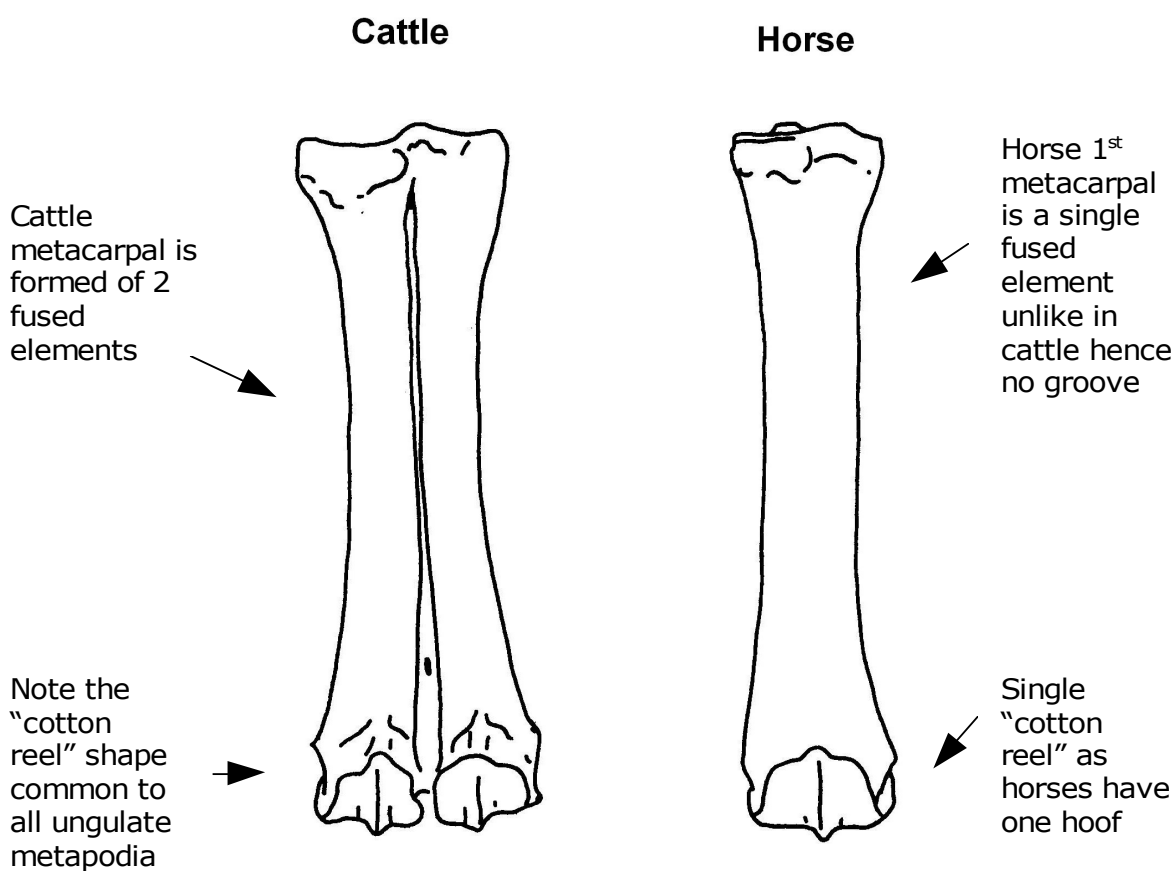


Figure 4: Cattle and horse 1st metacarpals

Horse astragali have a different shape to most ungulates due to the structure of the lower limb

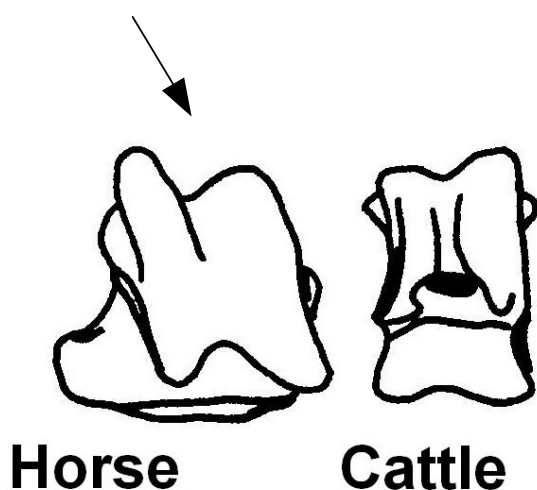


Figure 5: Horse and cattle astragali

Sheep versus Pig

As with cattle and horse remains, sheep and pigs are often confused due to their similar sizes. **Figure 6** shows the differences in sheep and pig skulls. The most notable difference is the much higher and flatter skull vault in pigs compared to sheep. Note also the different profile of the mandible. Luckily pig teeth are the most distinctive of the domestic mammals. **Figure 7** shows both pig and sheep molars. The different shape of the cusps on the pig tooth is immediately apparent and is very different from the “W” shaped profile of sheep teeth which look somewhat like miniature cattle teeth.

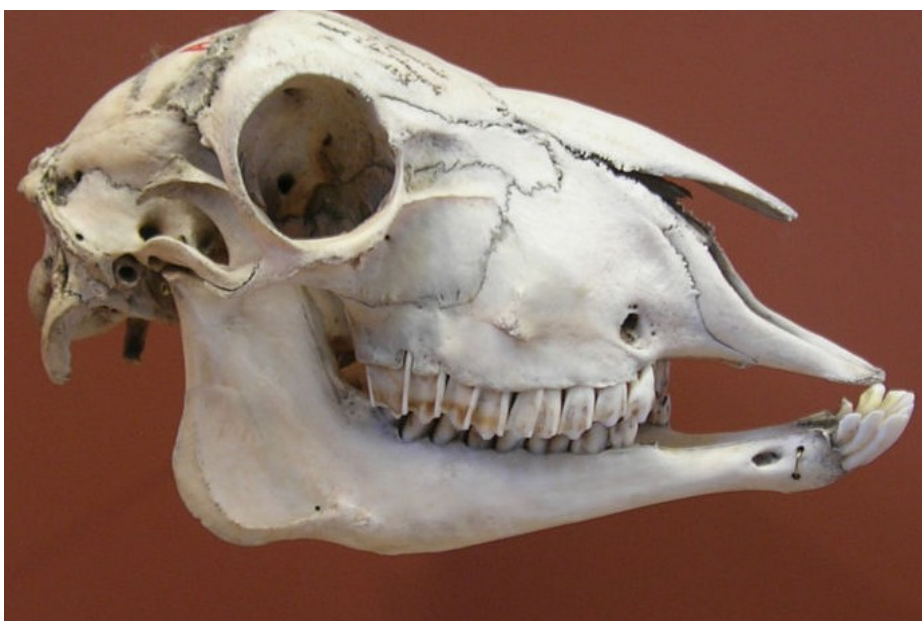
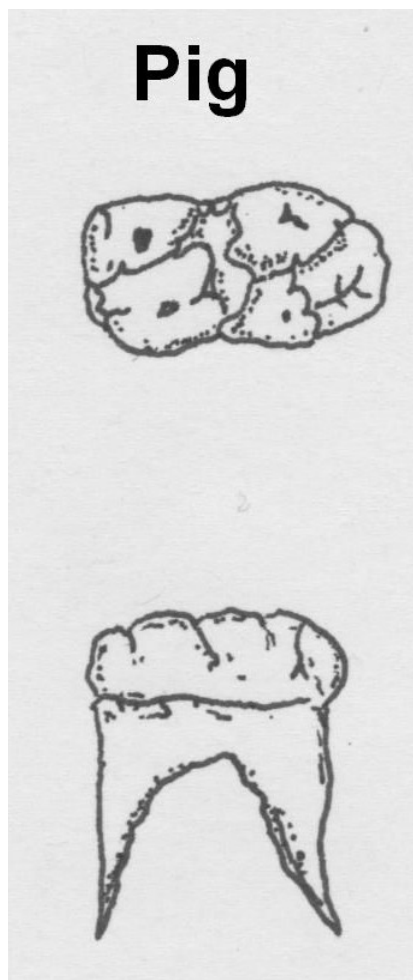
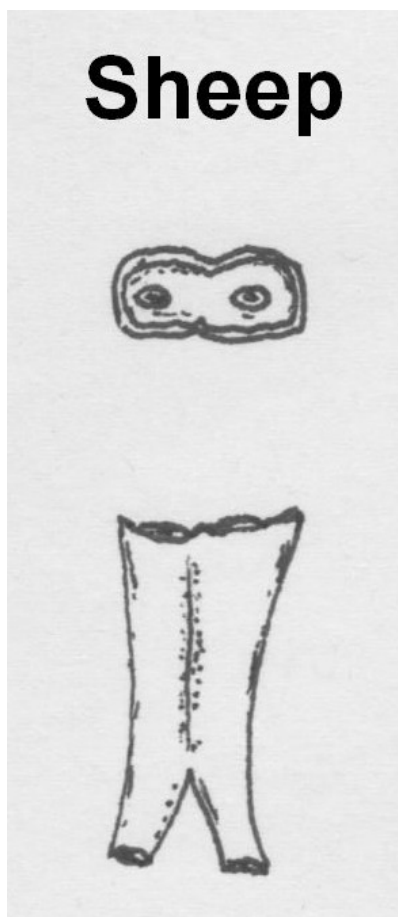


Figure 6: Sheep (top) and Pig (bottom) skulls



Note the complex fold pattern unique to pigs (fragmentary molars are easily confused with human teeth!)

Figure 7: Sheep and pig 1st molars (lower)

Morphological differences are also very apparent between sheep and pig scapulae, with the spine of the scapula in pigs being folded over and far more central to the blade than in sheep (see **Figure 8**). The shape of the lower limb (metapodia and phalanges) is more complex in pigs than sheep, with four distinct phalanges all unfused to one another, as opposed to sheep which have a single metacarpal comprised of two fused bones (see **Figure 9**). As with cattle this has resulted in a double “cotton reel” shape at the distal end in sheep.

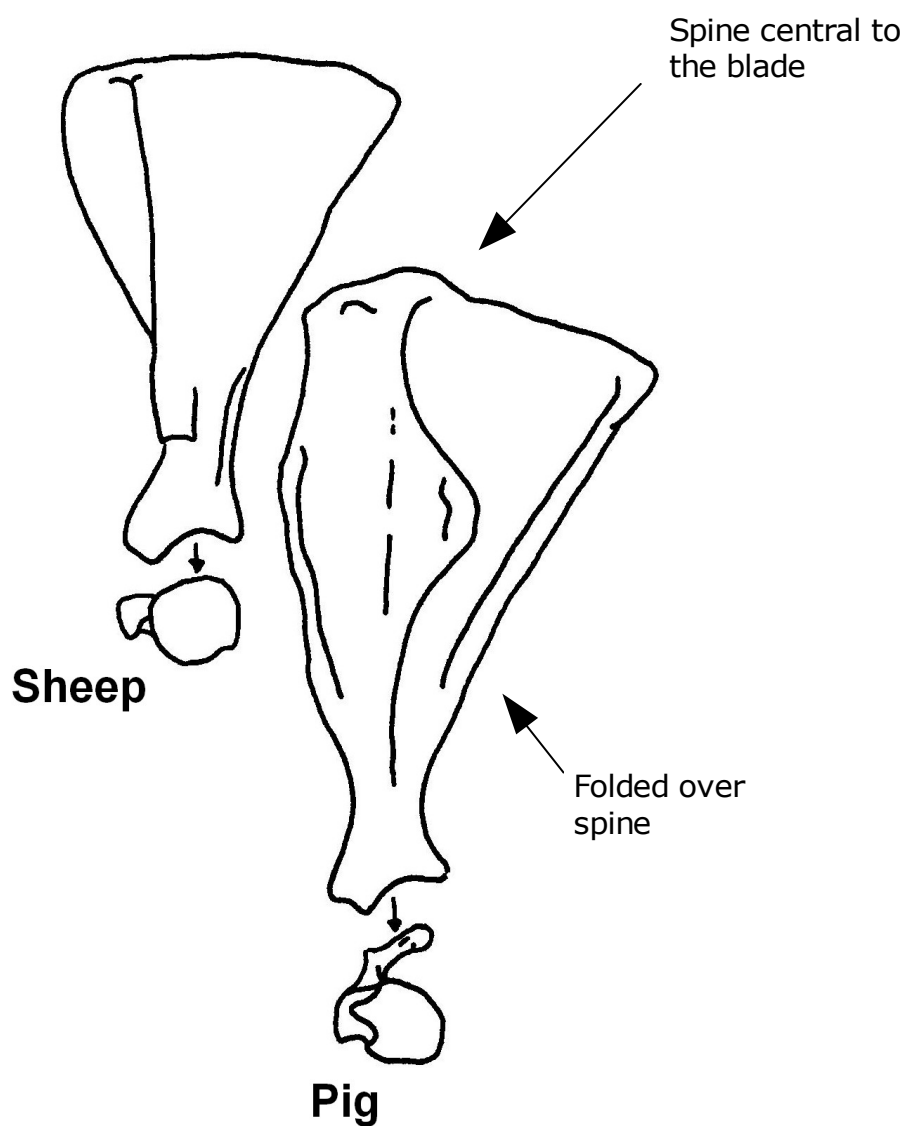


Figure 8: Sheep and pig scapulae

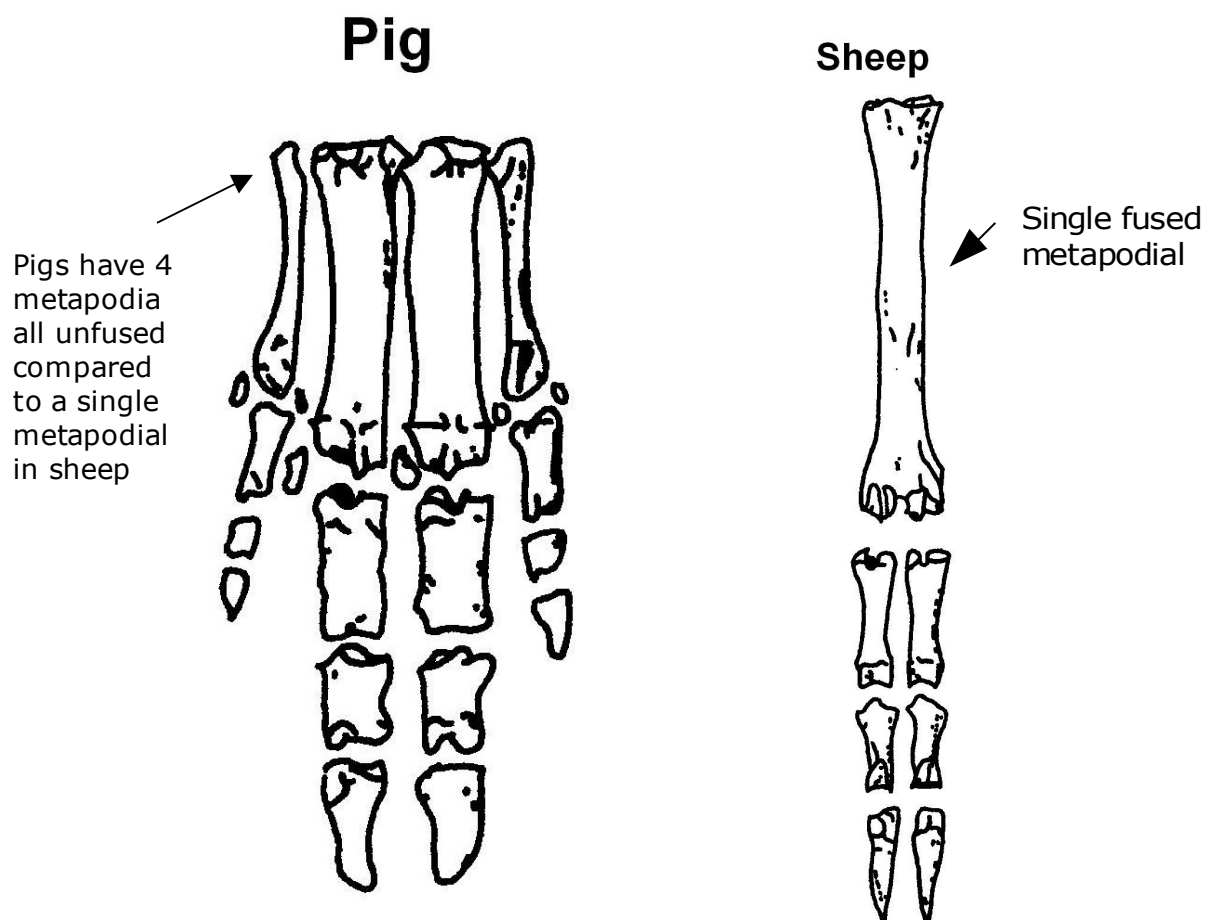


Figure 9: Pig and Sheep lower limbs

Dog vs Cat

Whilst differences in dogs and cats are largely beyond the scope of this introduction it is worth noting a difference in the distal humerus as its robusticity means it is the one of the most commonly found elements on archaeological sites. As one can see in **Figure 10**, both dog and cat humeri have a hole (*foramen*) through the distal articulation. In dogs this runs through the articulation whereas in cats it runs to the side.

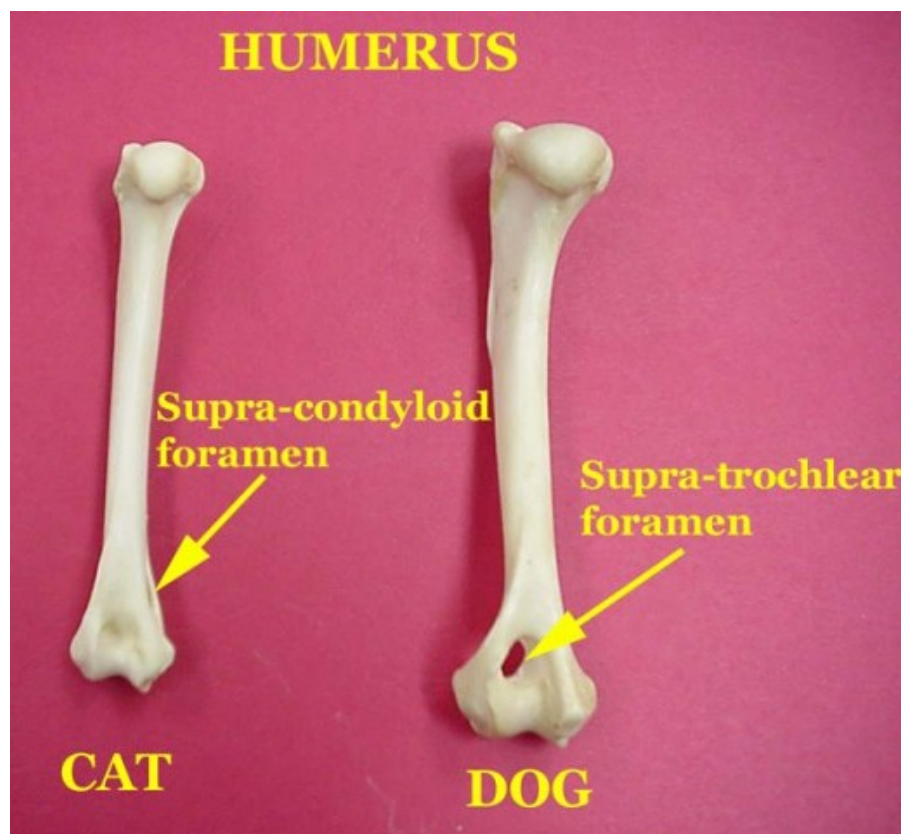


Figure 10: Cat and dog humerus

REFERENCES

As mentioned at the start of this guide it takes time gaining experience handling a variety of bones both on site and in reference collections to become proficient in identifying a wider range of species. However books can be extremely helpful. The most useful are listed below:

| | | |
|-------------------------------|------|--|
| Hillson, S. | 2002 | <i>Mammal Bones and Teeth: An Introductory Guide to Methods of Identification.</i> Left Coast Press. |
| Pales, C. and Lambert, L. | 1971 | <i>Atlas Osteologique pour servir a l'identification des Mammiferes du Quaternaire.</i> |
| Schmid, E. | 1972 | <i>Atlas of Animal Bones.</i> |
| White, T. | 2011 | <i>Human Osteology.</i> Third Edition. Academic Press. |
| Cohen, A. and Serjeantson, D. | 1991 | <i>Manual for the Identification of Bird Bones from Archaeological Sites.</i> |